

Supplement to

March 2018

# RT

Retina Today



## A New Chapter in Retina Surgery

Latest technologies and techniques.

SUPPORTED VIA ADVERTISING  
BY BAUSCH + LOMB



# CONTENTS

STELLARIS:  
THE EVOLUTION CONTINUES ..... 3

THE HYPERSONIC  
VITRECTOR: A NEW WAY ..... 5

AN OVERVIEW OF NEW TOOLS FOR  
VITREORETINAL SURGERY ..... 7

COMBINED CATARACT SURGERY  
AND PARS PLANA VITRECTOMY ..... 9

# STELLARIS: THE EVOLUTION CONTINUES

With its upgradable technology platform, the Stellaris Elite is capable of hypersonic vitrectomy.

BY CARL C. AWH, MD



I have a longstanding relationship with Bausch + Lomb and its vitrectomy devices. I was a fellow at the Duke Eye Center in 1990, when the Storz Premier was the machine of choice of all our faculty. I was among the first surgeons to perform transconjunctival 25-gauge vitrectomy, first introduced by Bausch + Lomb, and I've witnessed many advancements within the field of retinal surgery generally and with Bausch + Lomb's

vitrectomy line specifically. With that said, I think some of the most interesting things in retinal surgery are happening right now.

The next-generation vitrectomy machine, the Stellaris Elite (Figure 1), is an upgraded and upgradable technology platform. With a guillotine cutter speed of up to 15,000 cuts per minute (Bi-Blade dual-port cutter; Bausch + Lomb; Figure 2), the introduction of Hypersonic Vitrectomy, and the availability of a full portfolio of 23-, 25-, and 27-gauge instrumentation, this technology is hard to surpass in versatility, accuracy, and precision.

## TWO EXCITING DEVELOPMENTS

The two most exciting developments with the Stellaris are the Bi-Blade dual-port cutter and Vitesse hypersonic vitrectomy.

**Bi-Blade cutter.** The addition of the Bi-Blade dual-port cutter is an important upgrade, providing a substantial increase in cut rate. The Bi-Blade cutter has a port in both the inner and outer guillotine sleeves, which enables it to cut on both the down- and upstroke, for an effective cut rate of 15,000 cuts per minute. This advancement is particularly important in 27-gauge vitrectomy, where the increased cut rate improves flow through the smaller internal lumen. The mechanism of the Bi-Blade allows the port to remain open throughout the duty cycle at all cut rates, maintaining stable flow even at the highest cut rates. This results in excellent high flow during the core vitrectomy and precise and predictable low flow when working near mobile detached retina.

**Vitesse.** The most intriguing advancement with the Stellaris Elite is Vitesse, the technology that drives hypersonic vitrectomy. With Vitesse, the port remains constantly open, with what we can consider a 100% duty cycle, resulting in 1.7 million "virtual cuts" per minute. In my experience, Vitesse allows steady and uninterrupted vitreous flow.

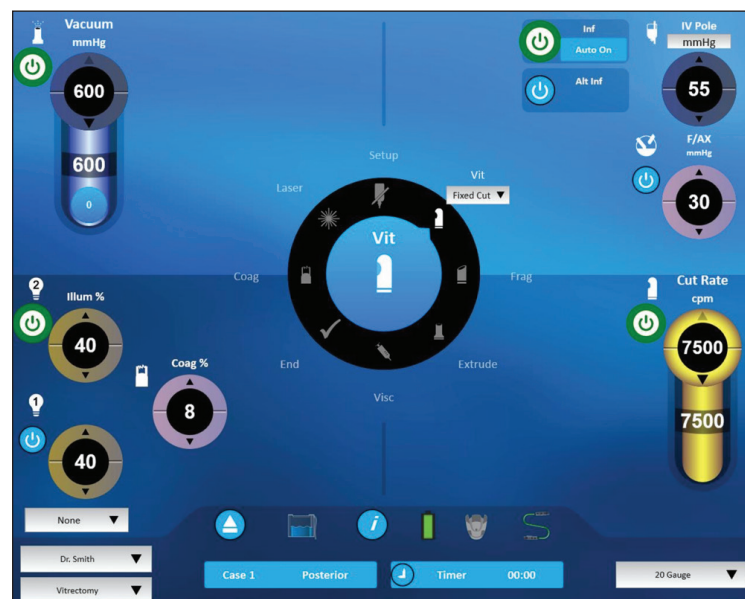

Figure 1. User interface of the Stellaris Elite.




Figure 2. The Bi-Blade dual-port cutter.

The electron microscopy images in Figure 3A come from the laboratory of Paulo E. Stanga, MD. These images show that a guillotine vitreous cutter creates short strands of collagen, but the hypersonic cutter seems to have created miniscule "dots" of collagen. This seems fundamentally different than "cutting" the vitreous. We term this effect *hypersonic liquefaction*, and it seems to dramatically

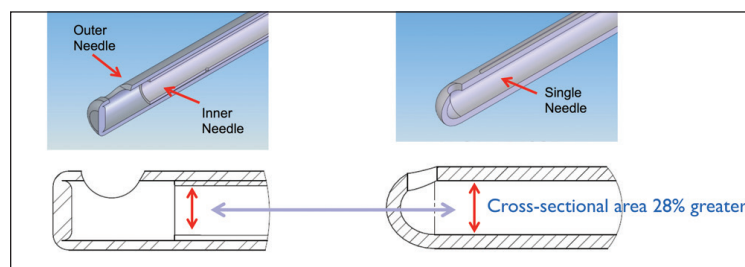
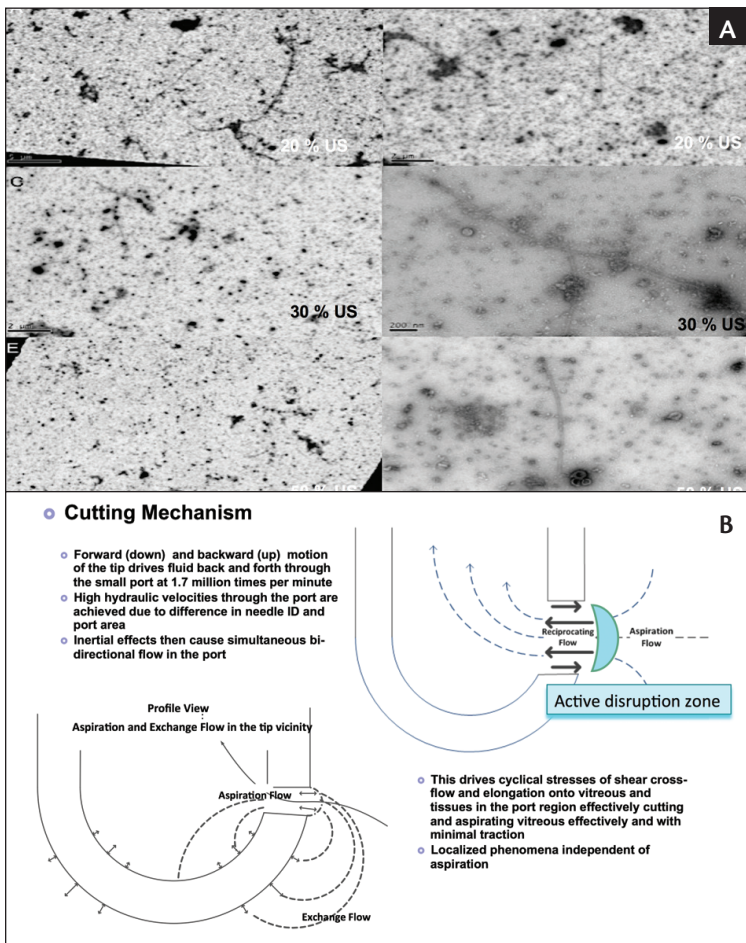


Figure 5. The single-lumen device has a cross-sectional area that is 28% larger in a 23-gauge probe.

surface of probe over this retinal fold. Even though I am touching the retina with the Vitesse at its maximum setting, there is no visible damage. It appears that the zone of tissue destruction is confined to the area of the port.

Another amazing capability of Vitesse is that I can remove 5000 centistoke silicone oil through the tiny port of the Vitesse. As is well known, if I tried to aspirate 5000-centistoke silicone oil through a conventional 20-gauge cutter, it would immediately clog. But I can easily extract this silicone oil out of the eye with a 23-gauge Vitesse cutter, because we really seem to be altering the mechanical properties of the aspirated oil.

## CONCLUSION

In summary, the Vitesse hypersonic liquefaction handpiece is a new Stellaris Elite accessory for posterior vitrectomy. It uses a novel single-needle probe with a continuously open port, making about 1.7 million “virtual cuts” per minute. It has potential advantages compared to conventional vitrectomy cutters, and the few first cases in humans have been done. Professor Stanga explains these cases in more detail in a subsequent article within this supplement.

I will be using the Vitesse device in human patients soon, and I look forward to reporting on my experience later this year. ■

CARL C. AWH, MD

■ Tennessee Retina

■ carlawh@gmail.com

■ Financial disclosure: Consultant (Bausch + Lomb)

change the mechanical properties of material as we remove it from the eye. This effect occurs at the outer margin of the port, with no apparent cutting effect by other parts of the tip, giving us much more freedom in the shape and location of the port. We are now experimenting with different port designs (Figure 4). The Vitesse technology even works with a curved probe, which may result in many options for new cutter geometries.

As I mentioned, the hypersonic liquefaction effect results in a localized zone of tissue liquefaction at the outer surface of the port. This may be significant because guillotine-type cutters only work after vitreous is pulled far enough through the port for the inner blade to cut it. Therefore, there is always a little traction created, which is eliminated when the “cutting” occurs at the surface. Whether eliminating that bit of traction related to the outer wall thickness is clinically relevant remains to be seen, but it is interesting. However, an obvious advantage is that, by eliminating the need for the inner guillotine tube, we now have a single-lumen device, with a much greater cross-sectional area—28% larger in a 23-gauge probe (Figure 5). This will improve flow, particularly important with smaller-gauge cutters.

The tissue damage effect of Vitesse is confined to the surface of the port. Further, I can actively remove vitreous while moving the back

# THE HYPERSONIC VITRECTOR: A NEW WAY

A number of perceived advantages are seen with this device.

BY PAULO E. STANGA, MD



I have been working with hypersonic vitrectomy technology since 2012. After many years of research and development in both porcine and human eyes, the concept of vitreous liquefaction has finally become a reality.

## UNDERSTANDING THE CONCEPT

During vitrectomy with a guillotine vitreous cutter, the vitreous is cut into small pieces. When higher cut rates are used with a guillotine cutter, shorter vitreous strands are created. These strands are not always cleanly cut, mainly because the fibers are being pulled into the port before they can be cut.

Alternatively, with hypersonic vitrectomy, the collagen fibers of the vitreous are pulverized in front of the port. In addition to this, the hypersonic handpiece has no inner needle and therefore no blade (Figure 1). Rather, the single-needle device moves up and down at a rate of 1.7 million virtual cuts per minute. This induces simultaneous bi-directional flow inside the port, which propels the collagen fibers in opposing directions, shredding them into very small pieces. These cyclical stresses of shear cross-flow and elongation onto the vitreous in the port region effectively liquefy the vitreous. The hypersonic effect is limited to an active zone in front of the port (Figure 2).

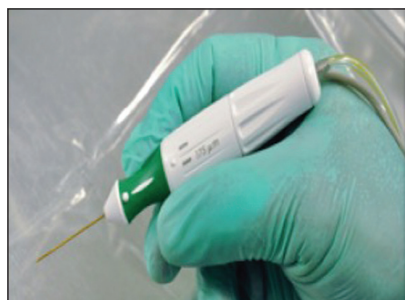

Figure 1. The hypersonic handpiece of the Stellaris Elite's Vitesse.

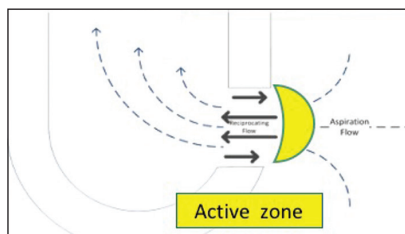


Figure 2. The hypersonic effect is limited to an active zone in front of the port.

## STUDYING THE TECHNOLOGY

In April 2017, the Vitesse, the technology used for hypersonic liquefaction, received FDA 510 clearance. In July 2017, we conducted a

study at Dr. Agarwal Eye Hospital in Chennai, India, to further assess the safety and efficacy of the hypersonic vitrector device in 20 eyes. Among them, there were nine macular holes, seven vitreous hemorrhages, three vitreoretinal tractions, and one pseudomacular hole.

The aim of the prospective, single-arm, noncomparative study was to further assess the safety and efficacy of the core vitrectomy and the ability of the hypersonic vitrector to induce a posterior vitreous detachment (PVD) and remove the peripheral vitreous. The average time to complete the hypersonic liquefaction was 8.9 minutes, and the mean surgical time was 67.8 minutes.

Core vitrectomies were accomplished in all cases, and peripheral vitrectomies were accomplished in 18 of 20 (90%) patients (Figure 3A). Induction of a PVD was successful in 12 of 15 (87%) patients for which a PVD was required (Figure 3B), and this is comparable to

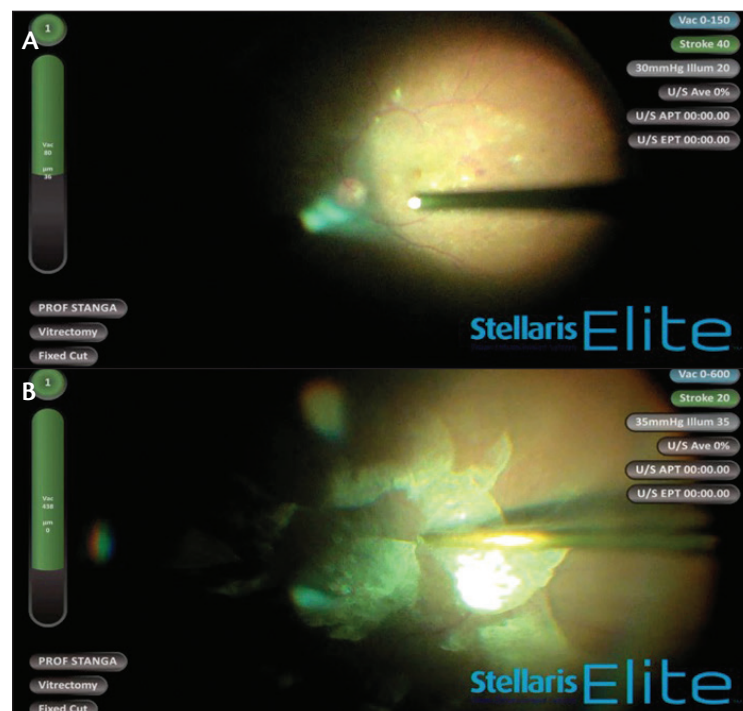


Figure 3. Core and periphery vitrectomy (A); induced PVD (B).

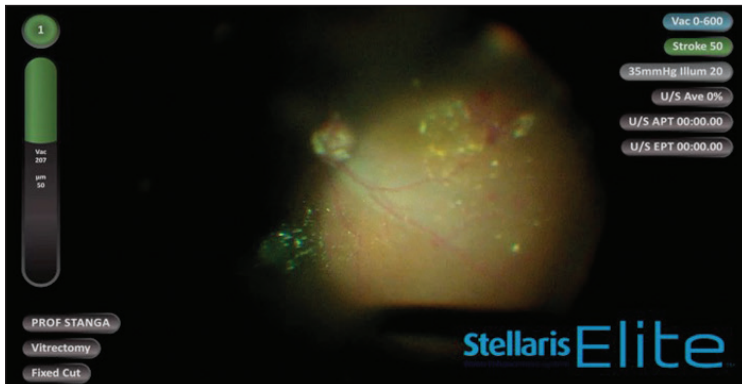


Figure 4. The backflush-like function of the hypersonic vitrector.

what can be achieved with a guillotine vitrector. From a safety standpoint, there were no unexpected adverse events: two of 20 patients experienced each two severe adverse event (SAE) involving retinal tears and retinal detachments that were considered device-related.

In order to induce a PVD, the posterior hyaloid is first highlighted with triamcinolone. Then the hypersonic vitrector is moved toward the vitreous and engaged, obtaining a complete PVD.

#### SURGICAL DETAILS

In my experience, I found it most advantageous in order to induce PVD to first do core vitrectomy, then engage the vitreous close to the optic nerve head without any stroke-induced PVD and then use stroke and release, repeating this sequence as necessary and over the four quadrants.

Because the port is so close to the tip, it is easy to aspirate the hemorrhage by hovering over the surface of the retina, and it is also easier to achieve a more complete fluid/air exchange. Additionally, the hypersonic vitrector has a backflush-like function that allows me to squirt a jet of the aspirated fluid onto the retina in order to displace hemorrhages or mobilize tissue (Figure 4). This is a convenient feature that saves another change of instruments.

#### PERCEIVED ADVANTAGES

For the time being, Vitesse is a promising additional tool for posterior vitrectomy. As more surgeons start using this technology, surgical techniques will develop and evolve and additional port configurations and gauges will become available. We expect these new advances to become very important, perhaps representing the strongest advantages of this new technology. ■

---


#### PAULO E. STANGA, MD

- Professor of Ophthalmology and Retinal Regeneration, Manchester Royal Eye Hospital, United Kingdom
- Director, Manchester Vision Regeneration Lab, United Kingdom
- [retinaspecialist@btinternet.com](mailto:retinaspecialist@btinternet.com)
- Financial disclosure: Consultant (Bausch + Lomb)

# AN OVERVIEW OF NEW TOOLS FOR VITREORETINAL SURGERY

A range of options for illumination and laser application broaden the capabilities of retina surgeons.

BY MICHAEL AMON, MD, FEBO



The indications for vitrectomy are myriad, from floaters to vision-threatening ocular trauma (Table 1), but, whatever the purpose of surgery, it is important that it be performed efficiently and effectively. A rapid, safe, efficient technique helps to minimize inflammation, mechanical trauma, and photochemical toxicity in the eye. It is especially vital to minimize light toxicity when surgery is focusing on the macula.

In recent years, instrumentation for vitrectomy has been continually improved in efforts to enhance surgical efficiency. We now have access to smaller-gauge vitrectomy handpieces; higher cutting rates; better fluidics, illumination, and tools; and improved laser probes than we did only a few years ago. In this article, I describe how some of these innovations have changed the face of vitrectomy surgery.

## SMALLER AND BETTER

Every surgeon has a different approach to vitreoretinal surgery. For decades, the standard for three-port pars plana vitrectomy required conjunctival openings and large incisions to accommodate the 20-gauge vitrector and other tools. The acceptance of this approach is waning as the advantages of smaller-gauge technologies become clear. Table 2 shows the diameters of the gauges now commonly used in retina surgery, ranging from 0.9 mm for 20-gauge down to less than half that diameter, 0.413 mm, with the latest available technology, 27-gauge. (Will 29-gauge eventually become a reality? Time will tell). For my routine approach, I now use 25-gauge technology, which is accommodated through 0.5-mm self-sealing incisions.

Efficient vitrectomy, as performed with 25-gauge and other small-gauge technologies, requires high vacuum and high cutting rates. With the cutting speeds available today, traction on the retina is minimized (Figure 1). Turbulence in the operative field is also reduced, as smaller, more finely chopped particles result in better fluidics and more laminar flow. Another key factor in efficient vitrectomy is the location of the port close to the distal end of the vitrectomy probe. Together, these design features allow surgeons to operate close to the retina, to handle tissues that are mobile, and to perform delicate maneuvers such as one-handed membrane peeling.

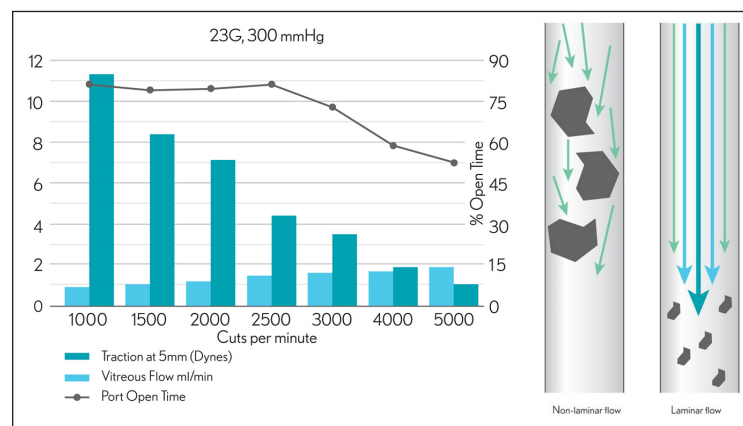


Figure 1. Today's available cutting speeds minimize traction on the retina.

## LET THERE BE LIGHT—BUT NOT TOO MUCH

Another vital element in efficient surgery is sufficient illumination. The goal of illumination in vitrectomy is to allow the surgeon to see what he or she is doing. This has been a challenge as gauges have shrunk, but the challenge has been met in some of the latest technologies. Xenon and mercury vapor light sources can provide brilliant illumination even through small gauges. Proper illumination helps to improve contrast when we are peeling thin, transparent membranes. Use of filtered light (Figure 2) or filters on the microscope also facilitate contrast in these situations.

An equally important goal of illumination, however, is to avoid damage to the patient's retina. There is a possibility of thermal damage as we operate close to the retina in macular

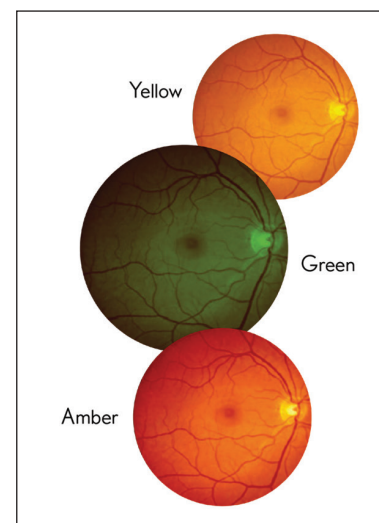


Figure 2. Yellow, green, and amber light filters.

TABLE 1. SELECTED INDICATIONS FOR VITRECTOMY

- Floater
- Asteroid hyalosis
- Edema
- Vitreoretinal traction
- Epiretinal membranes
- Macular hole
- Vitreous hemorrhage
- Retinal detachment
- Proliferative vitreoretinopathy
- Endophthalmitis, uveitis, parasites
- Trauma, intraocular foreign body

surgery. There is also the risk of light toxicity through photochemical effects on the retina. This phenomenon is well known in cataract surgery, and many surgeons use light filters, especially yellow light filters, during cataract removal. The problem is underappreciated in vitrectomy, where it can lead to a number of changes in the retina:<sup>1,2</sup>

- progressive loss of the outer retina;
- approximation of the deep capillary bed;
- vaso-obliterative changes;
- extensive pyknosis and reduction of nuclei in the outer nuclear layer;
- damage to ganglion cells; and
- edema formation.

There are several risk factors for phototoxic retinal damage, including the use of various prescription medications. One of the main factors, however, is the wavelength of the light itself. Therefore, it is essential that we optimize the light we use for visualization in vitrectomy.

### WORKING WITH FILTERS

Visualization in vitrectomy can be optimized with the use of dyes and/or filters on the light source or on the microscope. To minimize light toxicity, filters should be applied to the light source.

The Stellaris PC system (Bausch + Lomb) provides three types of filters: green, amber, and yellow. These can be used to modify the wide spectrum of the system's xenon lamp (Photon 1) and the high intensity of its xenon-mercury vapor lamp (Photon 2).

The surgeon can also help to decrease light toxicity by working as quickly as is safely possible, not spending too much time working in any area.

Monochromatic illumination with the yellow filter gives the surgeon the option to use higher power while maintaining safety. The yellow filter allows the use of brighter light with lower toxicity compared with white light.<sup>3</sup>

Bausch + Lomb acquired Synergetics in 2015, and the result is a




Figure 3. The directional laser probe tip.

range of versatile illumination tools for vitrectomy. These include wide-field, midfield, and focal illumination probes, each available in multiple gauges

TABLE 2. VITRECTOMY GAUGES IN MILLIMETERS

20 gauge	0.908 mm
23 gauge	0.642 mm
25 gauge	0.514 mm
27 gauge	0.413 mm
29 gauge*	0.337 mm
* technology yet to come	

to fit the type of surgery you want to perform. Chandelier designs are also available from the company, including the Oshima Dual chandelier that helps to eliminate shadows.

Chandelier lighting systems facilitate bimanual surgery and are helpful when no assistant surgeon is available. Adjustable chandelier systems allow direct fine-tuning of light intensity by hand, from focal to wide-field or from one angle to another; this can be done by the nurse so that the surgeon can continue bimanual maneuvers. The curved shape of the probes facilitates placement and enhances visibility, and the conic distal end enhances safety and avoids unexpected disconnection.

### A WORD ABOUT LASERS

A range of laser probes is also available for the Stellaris, including straight, curved, tapered, directional (Figure 3), aspirating, and illuminated. Soft-tip aspirating laser probes allow the surgeon to safely work close to the retina, providing simultaneous laser application and aspiration. Illuminated laser probes combine lighting and laser in one handpiece, allowing the surgeon to perform other maneuvers, such as scleral indentation, with the free hand. The illuminated combination also facilitates endolaser application in the periphery.

Intraoperative footpedal control of laser and other functions is another important element for achieving control of the operative environment. The wireless integrated dual-linear footpedal of the Stellaris PC helps to make surgery more efficient.

### CONCLUSION

Recent developments in surgical technologies, including smaller-gauge instrumentation, improved fluidics, and faster cutting speeds, have enhanced the safety and efficacy of vitrectomy surgery. At the same time, a wide range of options for illumination and laser application broaden the options for surgeons to be able to perform vitrectomy in the manner that best suits their needs and inclinations. ■

1. Banker AS, Freeman WR, Kim JW, Munguia D, Azen SP. Vision-threatening complications of surgery for full-thickness macular holes. Vitrectomy for Macular Holes Study Group. *Ophthalmology*. 1997;104(9):1442-1453.
2. Michels M, Lewis H, Abrams GW, Han DP, Mieler WF, Neitz J. Macular phototoxicity caused by fiberoptic endoillumination during pars plana vitrectomy. *Am J Ophthalmol*. 1992;114(3):287-296.
3. Chow DR. Tips on improving your use of endoillumination. *Retinal Physician*. May 2011.

### MICHAEL AMON, MD, FEBO

■ Professor and Head of Department of Ophthalmology, Academic Teaching Hospital of St. John, Vienna, Austria

■ amon@augenchirurg.com

■ Financial disclosure: Speaker (Bausch + Lomb)



# COMBINED CATARACT SURGERY AND PARS PLANA VITRECTOMY

Modern technology facilitates dual anterior- and posterior-segment procedures.

BY IGNASI JÜRGENS, MD, PhD



Cataract surgery and pars plana vitrectomy (PPV) are both surgical procedures commonly performed by ophthalmic surgeons. When cataract and vitreoretinal pathologies are present concomitantly in the same patient, it is possible to address both conditions in the same surgical session. This approach, combination cataract surgery and PPV, is currently more common in Europe than in the United States. However, recent

advances in instrumentation for vitrectomy and cataract surgery may now make the combination approach more interesting to US surgeons. In this article, I address some of the reasons for combining the two procedures, the indications and contraindications for combined surgery, and the ways modern vitrectomy and phacoemulsification technologies may facilitate this choice for ophthalmic surgeons.

## INDICATIONS

The indications for combined cataract surgery and PPV in patients with vitreoretinal pathologies include the following:

- significant vision loss caused by cataract;
- lens opacity that might prevent fundus visualization; and
- the need to perform clear lens extraction to access the vitreous space to address complex retinal detachment or complex retinal disease, such as recurrent vitreous hemorrhage in diabetic patients or persistent fetal vasculature in pediatric patients.

Other factors also may favor the use of a combined approach.

The indications for PPV generally increase in prevalence with aging because retinal diseases are more frequent in the aging population; at the same time, the prevalence of cataract increases with age. Further, the development or progression of cataract is almost always a consequence of PPV. As many as 80% of patients will experience development or progression of cataract after PPV, and, therefore, subsequently need to undergo cataract surgery.<sup>1-3</sup>

## DIFFERING APPROACHES

In the United States, as mentioned previously, cataract and vitreoretinal pathology are generally addressed separately. Two surgical

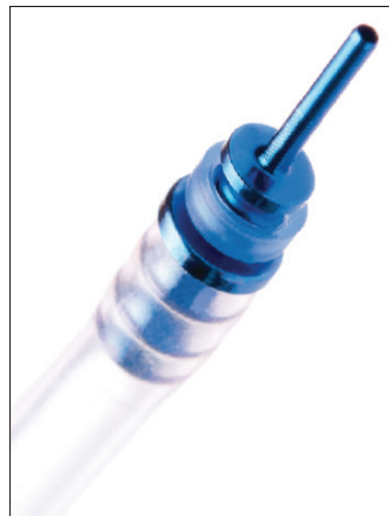

Figure 1. Valved trocar.

sessions are conducted sequentially by anterior segment and vitreoretinal surgeons. This subspecialist approach delays the final visual outcome for the patient and prolongs the period of recovery.

Depending on the order of the surgeries, there are separate concerns. If cataract surgery is performed first, it may exacerbate the vitreoretinal pathology. If cataract is performed after PPV, on the other hand, it may lead to recurrence of the pathology, such as reopening of macular holes or re-inflammation of macular edema. Another dis-

advantage for the cataract surgeon after PPV is that cataract surgery is more technically challenging in a vitrectomized eye and carries a greater risk of complications.

Among the challenges in phacoemulsification after PPV are the presence of an unstable posterior capsule and weakened zonules; the possibility that the lens-iris diaphragm may be excessively mobile, leading to fluctuation of the anterior chamber depth; and poor mydriasis.<sup>4-6</sup> There may be undetected tears in the posterior capsule that occurred during the previous PPV. Posterior capsular plaques may also be present after PPV, and these can be difficult to remove.<sup>6-9</sup>

Another factor affecting cataract surgery after PPV is that there is generally denser nuclear sclerosis, requiring increased ultrasound power or a chopping technique. This can increase intra- and postoperative corneal edema and inflammation.<sup>7</sup>

For these reasons, my indications for the use of a sequential approach are limited. I perform PPV alone when there is vitreoretinal

pathology in patients with no significant cataract, especially in younger patients who still have some degree of accommodation; in myopic patients to avoid postoperative anisometropia; and when the retinal pathology would limit visual recovery. I also perform PPV alone when the need for a second operation is guaranteed, as when silicone oil is used. Further, in patients in whom a scleral buckle will be placed, the delay of cataract surgery allows better fine tuning of the final refraction.

### COMBINED APPROACH

Outside the United States, cataract and vitreoretinal pathology are often addressed simultaneously by the same surgeon. Multiple studies have demonstrated the efficacy and safety of the combined approach in eyes with a variety of retinal pathologies, including macular hole, epiretinal membrane (ERM), proliferative diabetic retinopathy, and other complex posterior segment diseases.<sup>10-13</sup>

The combined approach reduces the surgical and economic burdens on the patient and the health care system with two surgical events. It minimizes risks of intraocular surgery and anesthesia, and it allows faster patient recovery and visual rehabilitation.<sup>10,11</sup>

Combining the surgeries also has advantages for the surgeon. Once the cataract is removed and an intraocular lens (IOL) implanted, the surgeon can achieve better visualization, both at the posterior pole for peeling membranes and in the peripheral anterior retina, looking for breaks. Removing the cataract also allows better access to the vitreous base without the fear of touching the lens.

On the other hand, the combined approach may carry the risk of increased corneal edema and miosis during surgery, inhibiting visualization. The prolonged combined surgical session may also elicit a greater inflammatory response.<sup>14,15</sup> Some surgeons have described a higher rate of posterior capsular opacification and of synechiae.<sup>10,14-16</sup>

Other potential disadvantages of combined surgery include the possibility that use of an intraoperative tamponade may increase the risk of IOL-related complications such as pupillary capture or IOL decentration.<sup>14,17</sup> Use of gas tamponade may also lead to displacement of the IOL, thereby inducing a myopic shift.<sup>18</sup>

### SURGICAL APPROACH FOR COMBINED CASES

Advances in surgical platforms have made combination surgery less challenging for the surgeon and improved results. For example, the Stellaris PC (Bausch + Lomb) platform combines the demonstrated performance of the Stellaris phacoemulsification system with full high-performance vitrectomy capability.

One of the helpful features of the Stellaris for cataract surgery is its dual-linear control footpedal, allowing independent control of vacuum and ultrasound. The venturi vacuum pump is highly efficient, especially during chopping techniques, helping to reduce the use of ultrasound power. The system is compatible with microincision cataract surgery (MICS) and microincision vitrectomy surgery (MIVS) techniques. Setup is fast and easy, which is important when there is a full surgical list for the day.



Figure 2. The enVista IOL.

In combined surgeries, the IOLs chosen should have an optic diameter of at least 6 mm to maximize visualization and should be rigid when unfolded in order to keep the capsular bag stable. This is especially important in patients who must maintain face-down positioning after intraoperative gas tamponade, to avoid anterior displacement of the IOL. One IOL that fits this bill is the enVista (Bausch + Lomb), a one-piece lens made with a hydrophobic acrylic material.

Careful attention to surgical maneuvers is advised when surgeons undertake the unique challenges of combined phacoemulsification and vitrectomy. There are two options for lens removal: phacoemulsification or lensectomy. Both have potential advantages and disadvantages.

Phacoemulsification is faster and allows implantation of the IOL into the capsular bag. Bag placement leads to better centration and better predictability, and it facilitates the use of premium IOLs. Phacoemulsification causes less uveal trauma than lensectomy but leads to higher endothelial cell loss.<sup>19</sup>

We use lensectomy only when we want to leave the patient aphakic. This posterior approach to lens removal causes less corneal edema during surgery, but it leads to dispersion of lens fragments into the vitreous cavity. It allows implantation of an IOL into the ciliary sulcus, but this is associated with pigment dispersion, uveitis, and risk of other IOL-related complications.

### SURGICAL PEARLS

Following are a few helpful pointers based on my technique for combined cataract and PPV surgery.

**Proper trocar placement is the first important step.** By inserting the trocars (Figure 1) first, we ensure that a closed system is maintained. If the trocars are inserted after cataract surgery, the pressure exerted on the globe can cause the corneal incisions to leak.

**My standard approach for phacoemulsification is through a 2.2-mm microincision.** Appropriate IOLs, as mentioned previously, with a minimum 6-mm optic and stiff haptics, do not fit through any smaller incisions.

It is important to protect the cornea with an ophthalmic viscosurgical device (OVD) to minimize epithelial and endothelial damage and to maintain good visualization throughout the procedure.

The capsulorrhexis should be well centered and slightly smaller

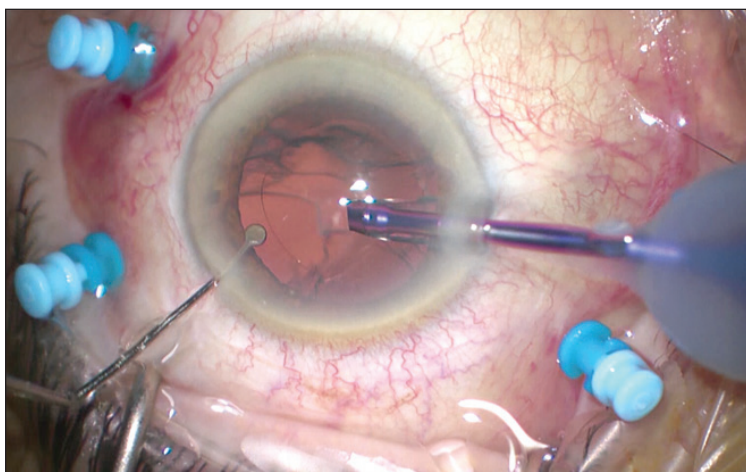


Figure 3. Combined cataract and vitrectomy surgery with the Stellaris PC.

in diameter than the optic of the IOL, approximately 5 mm. Hydrodissection should be performed carefully to avoid zonular stress and capsular rupture. I depress the corneal incision slightly to express some of the OVD and avoid elevating the intraocular pressure.

Phaco grooving should be performed, deep enough to avoid placing stress on the zonules when cracking the nucleus. I use a phaco needle designed for MICS. Intraoperative OCT is helpful to assess the depth of the groove.

With the venturi pump of the Stellaris PC, removal of lens fragments is efficient. Anterior chamber stability is maintained during fragment removal and subsequent irrigation and aspiration of cortex.

The OVD is again used to expand the capsular bag before IOL implantation. I routinely remove it after the IOL has been implanted. The controlled unfolding of the enVista IOL (Figure 2) makes this maneuver easy.

The corneal incisions are tested at the conclusion of the cataract/IOL portion of the procedure. They must be watertight because scleral depression will be performed during vitrectomy. If they are not watertight, a suture can be placed to ensure closure.

I routinely perform a posterior capsulotomy after placing the infusion line, and then we are ready to proceed to the vitrectomy portion of the combined surgery.

In a patient with an epiretinal membrane (ERM), the next step after vitrectomy is to inject dye to stain the membrane. I routinely use a combination of brilliant blue G and trypan blue. When staining is not as good as one would like, intraoperative OCT helps to identify the best places to grasp the edge of the ERM or internal limiting membrane. The intraoperative OCT also helps titrate the force and traction applied on the retinal surface as we pull the ERM with forceps. We routinely use intraoperative OCT to see if there is any residual membrane left after peeling.

When vitrectomy is complete, we ensure that the IOL is still centered and that the optic has not been captured by the capsulorrhexis.

Finally, after all cannulas are removed, we reposition the conjunctiva and check that there is no significant leakage from the wounds to avoid severe postoperative hypotony.

## CONCLUSION

Combined cataract and vitrectomy surgery (Figure 3) is effective and efficient. It offers many advantages over the sequential approach, including less surgical trauma, fewer complications, and faster visual recovery for the patient. For the surgeon it improves visualization during surgery, especially regarding access to the anterior retina. The few concerns specific to combined surgery, such as increased postoperative inflammation and potential for IOL-related complications, can be avoided by using optimal surgical techniques as outlined in this article. ■

- de Bustros S, Thompson JT, Michels RG, Enger C, Rice TA, Glaser BM. Nuclear sclerosis after vitrectomy for idiopathic epiretinal membranes. *Am J Ophthalmol*. 1988;105:160-164.
- Hsuan JD, Brown NA, Bron AJ, Patel CK, Rosen PH. Posterior subcapsular and nuclear cataract after vitrectomy. *J Cataract Refract Surg*. 2001;27:437-444.
- Melberg NS, Thomas MA. Nuclear sclerotic cataract after vitrectomy in patients younger than 50 years of age. *Ophthalmology*. 1995;102:1466-1471.
- Smiddy WE, Michels RG, Stark WJ, Maumenee AE. Cataract extraction after retinal detachment surgery. *Ophthalmology*. 1988;95:3-7.
- Sneed S, Parrish RK 2nd, Mandelbaum S, O'Grady G. Technical problems of extracapsular cataract extractions after vitrectomy. *Arch Ophthalmol*. 1986;104:1126-1127.
- Pinter SM, Sugar A. Phacoemulsification in eyes with past pars plana vitrectomy: case-control study. *J Cataract Refract Surg*. 1999;25:556-561.
- Grusha YO, Masket S, Miller KM. Phacoemulsification and lens implantation after pars plana vitrectomy. *Ophthalmology*. 1998;105:287-294.
- Biró Z, Kovacs B. Results of cataract surgery in previously vitrectomized eyes. *J Cataract Refract Surg*. 2002;28:1003-1006.
- Chang MA, Parides MK, Chang S, et al. Outcome of phacoemulsification after pars plana vitrectomy. *Ophthalmology*. 2002;109:948-954.
- Musielier A, Dugas B, Burelle X, et al. Macular hole surgery and cataract extraction: combined vs consecutive surgery. *Am J Ophthalmol*. 2010;150:387-391.
- Dugas B, Ouled-Moussa R, Lafontaine PO, et al. Idiopathic epiretinal macular membrane and cataract extraction: combined versus consecutive surgery. *Am J Ophthalmol*. 2010;149:302-306.
- Lee DY, Jeong HS, Sohn HJ, Nam DH. Combined 23-gauge sutureless vitrectomy and clear corneal phacoemulsification in patients with proliferative diabetic retinopathy. *Retina*. 2011;31:1753-1758.
- Sisk RA, Murray TG. Combined phacoemulsification and sutureless 23-gauge pars plana vitrectomy for complex vitreoretinal diseases. *Br J Ophthalmol*. 2010;94:1028-1032.
- Smith M, Raman SV, Pappas G, Simcock P, Ling R, Shaw S. Phacovitrectomy for primary retinal detachment repair in presbyopes. *Retina*. 2007;27:462-467.
- Treumer F, Bunse A, Rudolf M, Roeder J. Pars plana vitrectomy, phacoemulsification and intraocular lens implantation. Comparison of clinical complications in a combined versus two-step surgical approach. *Graefes Arch Clin Exp Ophthalmol*. 2006;244:808-815.
- Lahey JM, Francis RR, Kearney JJ. Combining phacoemulsification with pars plana vitrectomy in patients with proliferative diabetic retinopathy: a series of 223 cases. *Ophthalmology*. 2003;110:1335-1339.
- Rahman R, Rosen PH. Pupillary capture after combined management of cataract and vitreoretinal pathology. *J Cataract Refract Surg*. 2002;28:1607-1612.
- Shioya M, Ogino N, Shinjo U. Change in postoperative refractive error when vitrectomy is added to intraocular lens implantation. *J Cataract Refract Surg*. 1997;23:1217-1220.
- Eom Y, Kim SW, Ahn J, Kim JT, Huh K. Comparison of cornea endothelial cell counts after combined phacovitrectomy versus pars plana vitrectomy with fragmentation. *Graefes Arch Clin Exp Ophthalmol*. 2013;251(9):2187-2193.

## IGNASI JÜRGENS, MD, PhD

■ Centre Oftalmològic Barcelona

■ Institut Català de Retina

■ jurgens@comb.cat

■ Financial disclosure: Speaker (Bausch + Lomb)

Indications and approvals may vary by country.  
[bauschsurgical.eu](http://bauschsurgical.eu)